

CORRECTION

Open Access



Correction: DACH1 antagonizes CXCL8 to repress tumorigenesis of lung adenocarcinoma and improve prognosis

Qian Liu^{1†}, Anping Li^{2†}, Shengnan Yu¹, Shuang Qin¹, Na Han¹, Richard G. Pestell³, Xinwei Han^{2*} and Kongming Wu^{1*}

Correction: *Journal of Hematology & Oncology* (2018) 11:53
<https://doi.org/10.1186/s13045-018-0597-1>

The original article contained errors in Fig. 7. A549 vector in panel **a** should be labelled as vehicle and was duplicated with A549 vector in panel **c**. SKLU DACH1

in panel **e** should be labelled SKLU DACH1-vehicle, and was duplicated with SKLU CXCL-Ab in panel **a**. We repeated this experiment and presented right images with corresponding analysis.

(See figure on next page.)

Fig. 7 Overexpression of DACH1 controlled the CXCL8-induced migration of lung cancer cell in vitro. **a** Anti-CXCL8 antibody controlled the migration of SKLU and A549 cell lines, **b** the corresponding quantitative graph showed statistical significance. **c** The migration of ADC cells was inhibited in the presence of excessive DACH1 expression, **d** the corresponding quantitative graph showed statistical significance. **e** Human CXCL8 cytokine restored the DACH1-induced migration inhibition of SKLU-DACH1 and A549-DACH1 cells, **f** the corresponding quantitative graph showed statistical significance

The original article can be found online at <https://doi.org/10.1186/s13045-018-0597-1>.

[†]Qian Liu and Anping Li: Equal contributors

*Correspondence: hanxinwei2006@163.com; kmwu@tjh.tjmu.edu.cn

¹ Department of Oncology, Tongji Hospital of Tongji Medical College, Huazhong University of Science and Technology, Wuhan 430030, People's Republic of China

² Department of Interventional Radiology, The First Affiliated Hospital of Zhengzhou University, Zhengzhou 450052, People's Republic of China
Full list of author information is available at the end of the article



© The Author(s) 2022. **Open Access** This article is licensed under a Creative Commons Attribution 4.0 International License, which permits use, sharing, adaptation, distribution and reproduction in any medium or format, as long as you give appropriate credit to the original author(s) and the source, provide a link to the Creative Commons licence, and indicate if changes were made. The images or other third party material in this article are included in the article's Creative Commons licence, unless indicated otherwise in a credit line to the material. If material is not included in the article's Creative Commons licence and your intended use is not permitted by statutory regulation or exceeds the permitted use, you will need to obtain permission directly from the copyright holder. To view a copy of this licence, visit <http://creativecommons.org/licenses/by/4.0/>. The Creative Commons Public Domain Dedication waiver (<http://creativecommons.org/publicdomain/zero/1.0/>) applies to the data made available in this article, unless otherwise stated in a credit line to the data.

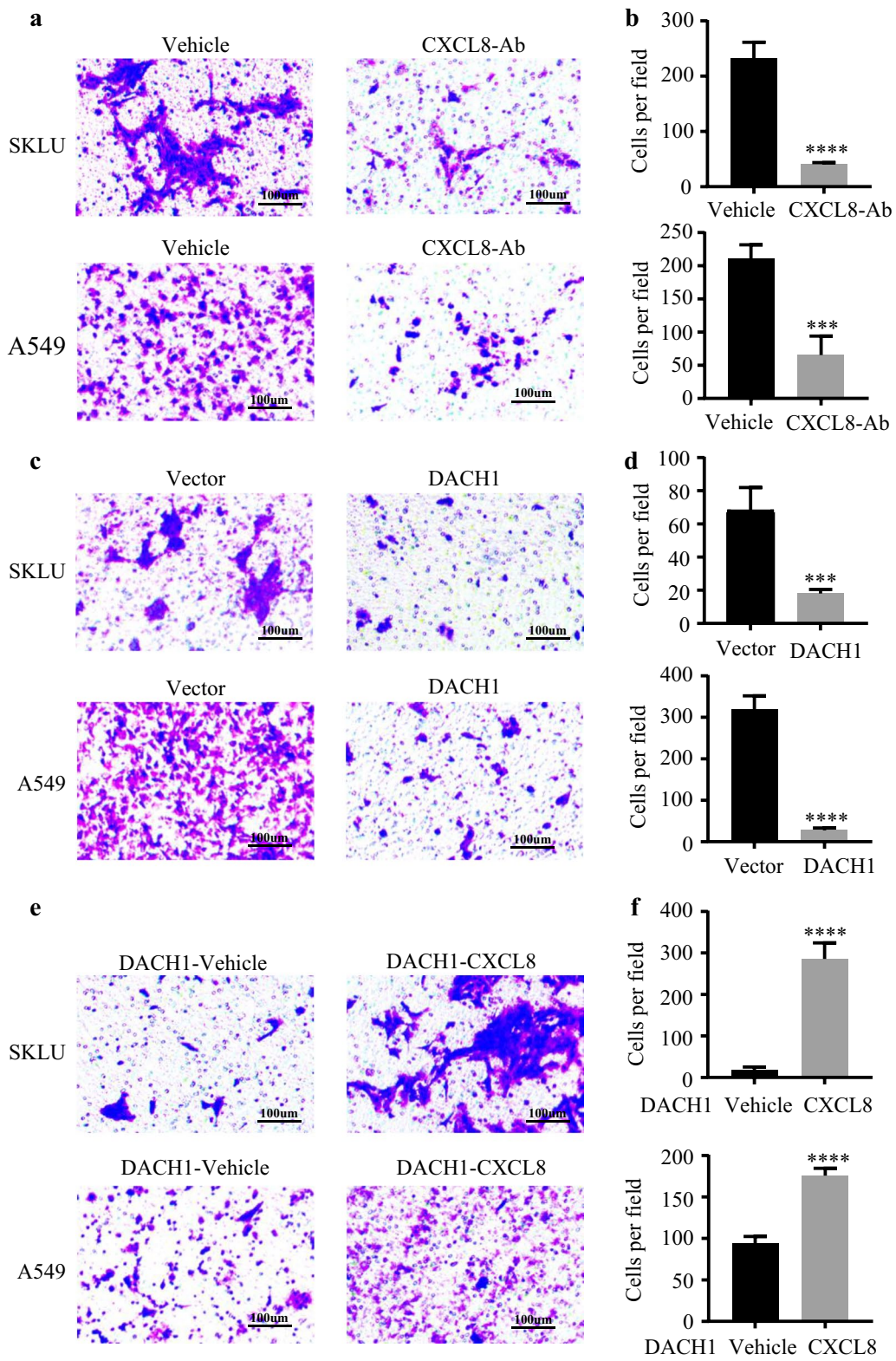


Fig. 7 (See legend on previous page.)

Author details

¹Department of Oncology, Tongji Hospital of Tongji Medical College, Huazhong University of Science and Technology, Wuhan 430030, People's Republic of China. ²Department of Interventional Radiology, The First Affiliated Hospital of Zhengzhou University, Zhengzhou 450052, People's Republic of China. ³Pennsylvania Cancer and Regenerative Medicine Research Center, Wynnwood, PA 19096, USA.

Published online: 13 December 2022

Publisher's Note

Springer Nature remains neutral with regard to jurisdictional claims in published maps and institutional affiliations.